

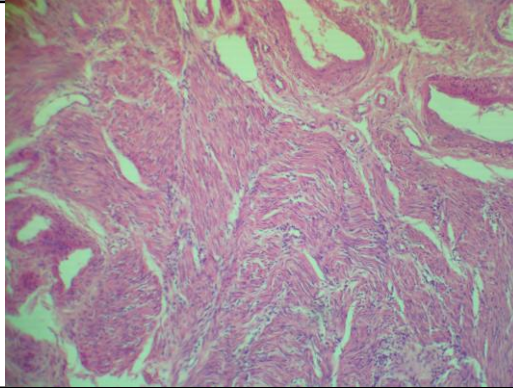
Patient Name	Mr. KURSHID	Client Name	Family Hospital and Surgical Centre	Specimen Received	28/02/2020
Age/Sex	34YRS/M			Specimen Type	Tissue
Patient ID	012002280150			Collection Date	28/02/2020
Specimen ID	MOLQ/B-497-20			Report Date	02/03/2020

SURGICAL PATHOLOGY REPORT

Gall Bladder

DIAGNOSIS

CHOLECYSTITIS AND CHOLELITHIASIS.



SPECIMEN

Gall Bladder

GROSS

Received 9x2.1 cm long gall bladder. Cut section shows stones.


Microscopy

Section examined shows ulcerative mucosa and Rokitansky-Aschoff sinus (irregularly shaped tubular structures lined by cuboidal lining epithelium with round to oval nucleus) with fibrocollagenous tissue and inflammatory cells (lymphocytes).

Note : All biopsy specimen will be stored for 15 (fifteen) days, block and slides for 5 (five) years only from the time of receipt at the laboratory. No request, for any of the above, will be entertained after the due date.

Reference

- i) Rosai and Ackerman's Surgical Pathology.
- ii) Modern Surgical Pathology.


Gulshan Yadav, MD
Consultant Pathologist