

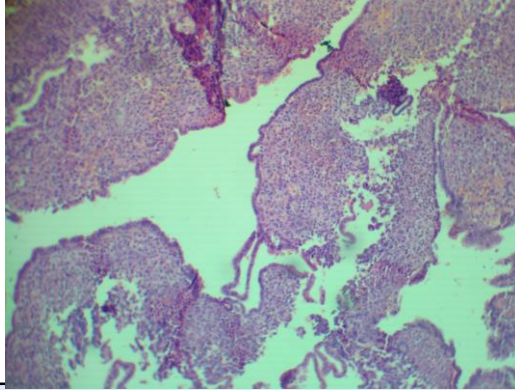
Patient Name	Mrs. SUDESH	Client Name	Delhi Hospital & Maternity Home	Specimen Received	28/02/2020
Age/Sex	45YRS/F			Specimen Type	Tissue
Patient ID	012002280014			Collection Date	28/02/2020
Specimen ID	MOLQ/B-491-20			Report Date	02/03/2020

SURGICAL PATHOLOGY REPORT

Endometrium

DIAGNOSIS

DISORDERED PROLIFERATIVE PHASE



SPECIMEN

Endometrium

GROSS

Received multiple grayish white tissue piece.

Microscopy

Section examined shows small and tortuous endometrial glands with cuboidal to columnar lining with small round nucleus. Stroma shows mononuclear inflammatory cells.

No granuloma seen. No malignant cells seen.

Note : All biopsy specimen will be stored for 15 (fifteen) days, block and slides for 5 (five) years only from the time of receipt at the laboratory. No request, for any of the above, will be entertained after the due date.

Reference

- i) Rosai and Ackerman's Surgical Pathology.
- ii) Modern Surgical Pathology.

Gulshan Yadav, MD
Consultant Pathologist