

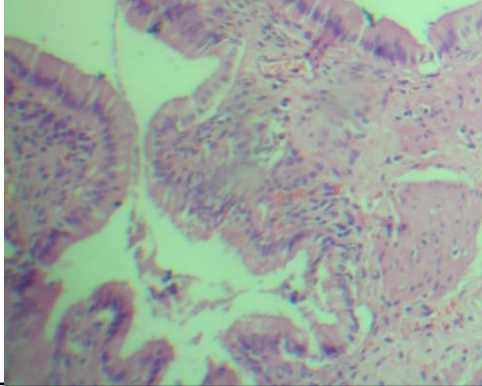
Patient Name	Mr. AZLAN S/O GH NABI	Client Name	A-One Collection Centre, Jammu & Kashmir	Specimen Received	27/02/2020
Age/Sex	19YRS/M			Specimen Type	Tissue
Patient ID	042002270035			Collection Date	27/02/2020
Specimen ID	MOLQ/B-469-20			Report Date	02/03/2020

SURGICAL PATHOLOGY REPORT

Gall Bladder

DIAGNOSIS

CHOLECYSTITIS.



SPECIMEN

Gall Bladder

GROSS

Received 5x2.4 cm long gall bladder. Cut section shows no stones. Wall thickness 0.4 mm.

Section examined shows ulcerative mucosa and rokitansky aschoff sinus (irregularly shaped

tubular structures lined by cuboidal lining epithelium with round to oval nucleus) with fibrocollagenous tissue and inflammatory cells (lymphocytes).

Note : All biopsy specimen will be stored for 15 (fifteen)days, block and slides for 5(five) years only from the time of receipt at the laboratory. No request ,for any of the above ,will be entertained after the due date.

Reference

- i) Rosai and Ackerman's Surgical Pathology.
- ii) Modern Surgical Pathology.

Gulshan Yadav, MD
Consultant Pathologist