

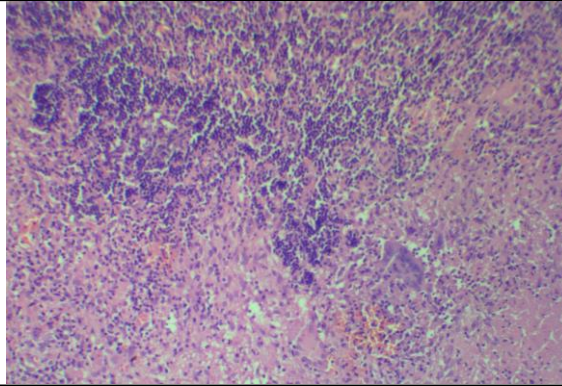
Patient Name	Mrs. LATA	Client Name	Dr Heart Path Lab C/o	Specimen Received	27/02/2020
Age/Sex	27YRS/F		Navjeevan Hospital &	Specimen Type	Tissue
Patient ID	012002270314		Maternity Center	Collection Date	27/02/2020
Specimen ID	MOLQ/B-477-20			Report Date	02/03/2020

SURGICAL PATHOLOGY REPORT

Right Axillary Lymph Nodes

DIAGNOSIS

GRANULOMATOUS REACTION (Tubercular pathology)



SPECIMEN

Right Axillary Lymph Nodes

GROSS

Received multiple grayish white tissue piece, 3.1x2 cm in aggregate.

Microscopy

Section examined shows lymphoid follicles with epithelioid cells with granuloma formation having caseous necrosis, epithelioid cells and multinucleated giant cells.

Note : All biopsy specimen will be stored for 15 (fifteen) days, block and slides for 5 (five) years only from the time of receipt at the laboratory. No request, for any of the above, will be entertained after the due date.

Reference

- i) Rosai and Ackerman's Surgical Pathology.
- ii) Modern Surgical Pathology.

Gulshan Yadav, MD
Consultant Pathologist