

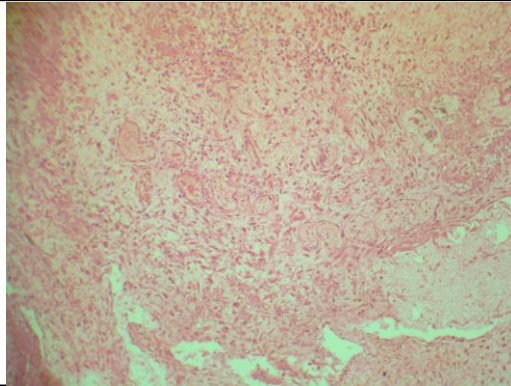
Patient Name	Mrs. ALKA KAPOOR	Client Name	Civil Hospital Sec-10	Specimen Received	26/02/2020
Age/Sex	40YRS/F			Specimen Type	Tissue
Patient ID	092002260027			Collection Date	26/02/2020
Specimen ID	MOLQ/B-485-20			Report Date	02/03/2020

SURGICAL PATHOLOGY REPORT

Endometrium

DIAGNOSIS

BLEEDING ENDOMETRIUM.



SPECIMEN

Endometrium

GROSS

Received multiple grayish white tissue piece.


Microscopy

Paucicellular section examined shows tissue with degenerative changes with polymorphs, fibrin, blood clot and macrophages. No endometrial glands seen in the sample received. No granuloma seen. No malignant cells seen.

Note : All biopsy specimen will be stored for 15 (fifteen) days, block and slides for 5 (five) years only from the time of receipt at the laboratory. No request, for any of the above, will be entertained after the due date.

Reference

- i) Rosai and Ackerman's Surgical Pathology.
- ii) Modern Surgical Pathology.


Gulshan Yadav, MD
Consultant Pathologist