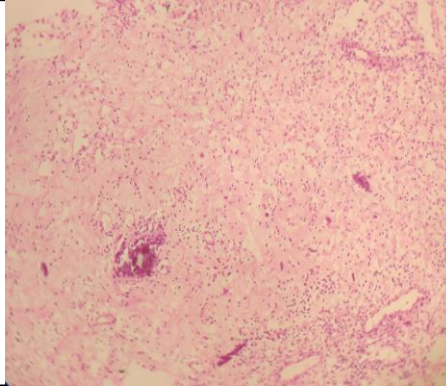


<b>Patient Name</b>	Master. REYAN	<b>Client Name</b>	Pushpanjali Hospital (Rewari)	<b>Specimen Received</b>	27/02/2020
<b>Age/Sex</b>	02YRS/M			<b>Specimen Type</b>	Tissue
<b>Patient ID</b>	012002270308			<b>Collection Date</b>	27/02/2020
<b>Specimen ID</b>	MOLQ/B-475-20			<b>Report Date</b>	02/03/2020

**SURGICAL PATHOLOGY REPORT**  
**Osteomyelitic Cranial Bone**

**DIAGNOSIS**

**CHRONIC SUPPURATIVE OSTEOMYELITIS**



**SPECIMEN**

Osteomyelitic Cranial Bone

**GROSS**

Received multiple grayish white tissue piece with bony fragments.

**Microscopy**

Section examined shows dead bony trabeculae (suggestive of sequestrum) surrounded by admixed population of neutrophils, lymphocytes and plasma cells. Section examined shows fibrosis and blood vessels.

No malignant cells seen.

**Note :** All biopsy specimen will be stored for 15 (fifteen)days, block and slides for 5(five) years only from the time of receipt at the laboratory. No request ,for any of the above ,will be entertained after the due date.

**Reference**

- i) Rosai and Ackerman's Surgical Pathology.
- ii) Modern Surgical Pathology.

**Gulshan Yadav, MD**  
**Consultant Pathologist**