

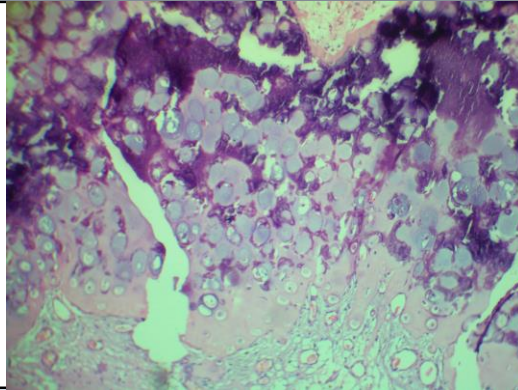
Patient Name	Ms. ANISHA 40441	Client Name	Pushpanjali Hospital (Rewari)	Specimen Received	26/02/2020
Age/Sex	18YRS/F			Specimen Type	Tissue
Patient ID	012002260300			Collection Date	26/02/2020
Specimen ID	MOLQ/B-459-20			Report Date	02/03/2020

SURGICAL PATHOLOGY REPORT

Swelling Right Distal Thigh

DIAGNOSIS

OSTEOCHONDROMA
CONSENSUS WITH THE CLINICAL FINDINGS.



SPECIMEN

Swelling Right Distal Thigh

GROSS

Received 3x4 cm bony tissue piece, covered with creamish white fibrous tissue suggestive of cartilagenous tissue.

Microscopy

1. Section examined shows presence of mature hylaine cartilage alongwith mature bony trabeculae embedded with osteocytic lacunae and rimmed with osteoblasts.
2. Presence of osteoid formation is also evident.
3. No granuloma seen.
4. No malignant cells seen.

Note : All biopsy specimen will be stored for 15 (fifteen)days, block and slides for 5(five) years only from the time of receipt at the laboratory. No request ,for any of the above ,will be entertained after the due date.

Reference

- i) Rosai and Ackerman's Surgical Pathology.
- ii) Modern Surgical Pathology.

Gulshan Yadav, MD
Consultant Pathologist