

Patient Name Master. SACHIN
Age/Sex 14YRS/M
Patient ID 012002260289
Specimen ID MOLQ/B-467-20

Client Name Sheetla Hospital, Gurgaon

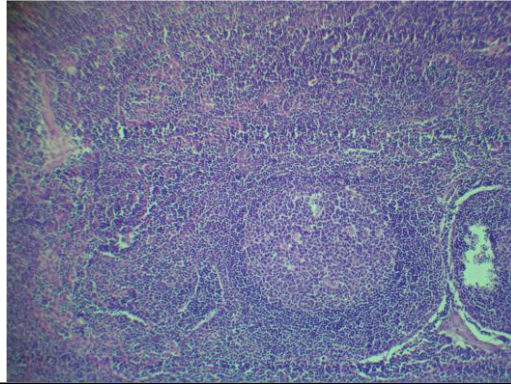
Specimen Received 26/02/2020
Specimen Type Tissue
Collection Date 26/02/2020
Report Date 02/03/2020

SURGICAL PATHOLOGY REPORT

Lymph Node

DIAGNOSIS

REACTIVE LYMPHADENITIS



SPECIMEN

Lymph Node

GROSS

Received 1x1 cm grayish white tissue piece.

Microscopy

Section examined shows preserved architecture of lymphoid follicles with surrounding fibrocollagenous tissue and blood vessels suggestive of capsule. Presence of dilated sinuses are also evident.

No granuloma seen. No malignant cells seen.

Note : All biopsy specimen will be stored for 15 (fifteen) days, block and slides for 5 (five) years only from the time of receipt at the laboratory. No request, for any of the above, will be entertained after the due date.

Reference

- i) Rosai and Ackerman's Surgical Pathology.
- ii) Modern Surgical Pathology.



Gulshan Yadav, MD
Consultant Pathologist