

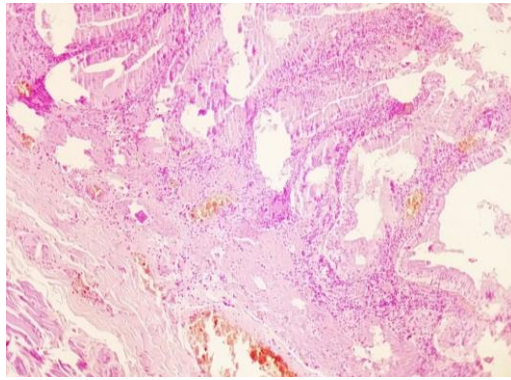
<b>Patient Name</b>	Mr. M. MUSTAFA	<b>Client Name</b>	Bandipora Collection Centre, Jammu & Ka	<b>Specimen Received</b>	25/02/2020
<b>Age/Sex</b>	25YRS/M			<b>Specimen Type</b>	Tissue
<b>Patient ID</b>	012002250345			<b>Collection Date</b>	25/02/2020
<b>Specimen ID</b>	MOLQ/B-446/19			<b>Report Date</b>	28/02/2020

## SURGICAL PATHOLOGY REPORT

### Gall Bladder

#### DIAGNOSIS

**CHOLECYSTITIS.**



#### SPECIMEN

Gall Bladder

#### GROSS

Received 4.5x2.8 cm long gall bladder without stones.  
Wall Thickness 0.3 mm.


#### Microscopy

Section examined shows ulcerative mucosa and Rokitansky-Aschoff sinus (irregularly shaped tubular structures lined by cuboidal lining epithelium with round to oval nucleus) with fibrocollagenous tissue and inflammatory cells (lymphocytes).

**Note :** All biopsy specimen will be stored for 15 (fifteen) days, block and slides for 5 (five) years only from the time of receipt at the laboratory. No request, for any of the above, will be entertained after the due date.

#### Reference

- i) Rosai and Ackerman's Surgical Pathology.
- ii) Modern Surgical Pathology.

  
**Gulshan Yadav, MD**  
**Consultant Pathologist**