

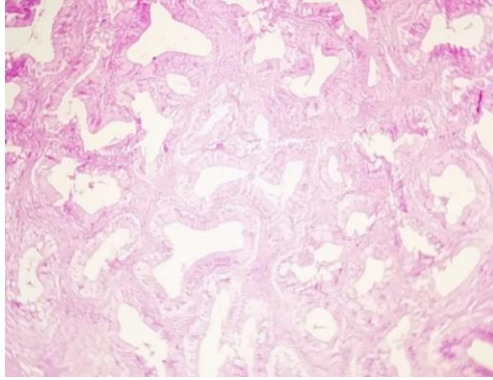
Patient Name	Ms. MEENA	Client Name	Umkal Hospital	Specimen Received	25/02/2020
Age/Sex	22YRS/F			Specimen Type	Tissue
Patient ID	012002250098			Collection Date	25/02/2020
Specimen ID	MOLQ/B-439-20			Report Date	28/02/2020

SURGICAL PATHOLOGY REPORT

Gall Bladder

DIAGNOSIS

CHOLECYSTITIS.



SPECIMEN

Gall Bladder

GROSS

Received 6X2.9 cm long gall bladder. Cut section shows no stones. Wall Thickness 0.2 mm.

Microscopy

Section examined shows ulcerative mucosa and Rokitansky-Aschoff sinus (irregularly shaped tubular structures lined by cuboidal lining epithelium with round to oval nucleus) with fibro collagenous tissue and inflammatory cells (lymphocytes).

Note : All biopsy specimen will be stored for 15 (fifteen)days, block and slides for 5(five) years only from the time of receipt at the laboratory. No request ,for any of the above ,will be entertained after the due date.

Reference

- i) Rosai and Ackerman's Surgical Pathology.
- ii) Modern Surgical Pathology.

Gulshan Yadav, MD
Consultant Pathologist