

Patient Name Mrs. KELO DEVI
Age/Sex 58YRS/F
Patient ID 012002230004
Specimen ID MOLQ/B-421/2020

Client Name S. M. Diagnostics, Kaithal

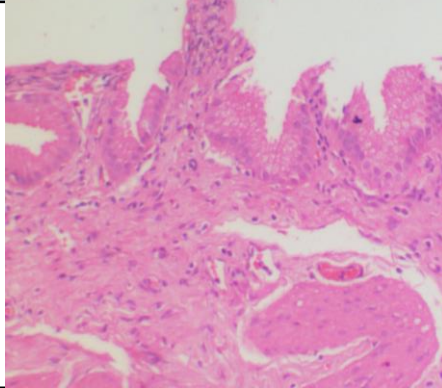
Specimen Received 23/02/2020
Specimen Type Tissue
Collection Date 23/02/2020
Report Date 27/02/2020

SURGICAL PATHOLOGY REPORT

Gall Bladder

DIAGNOSIS

CHOLECYSTITIS AND CHOLELITHIASIS.



SPECIMEN

Gall Bladder

GROSS

Received 8x3cm long gall bladder. Cut section shows stones. Wall thickness 0.3mm.


Microscopy

Section examined shows ulcerative mucosa and Rokitansky-Aschoff sinuses (irregularly shaped tubular structures lined by cuboidal lining epithelium with round to oval nucleus) with fibro collagenous tissue and inflammatory cells (lymphocytes).

Note : All biopsy specimen will be stored for 15 (fifteen) days, block and slides for 5 (five) years only from the time of receipt at the laboratory. No request, for any of the above, will be entertained after the due date.

Reference

- i) Rosai and Ackerman's Surgical Pathology.
- ii) Modern Surgical Pathology.


Gulshan Yadav, MD
Consultant Pathologist