

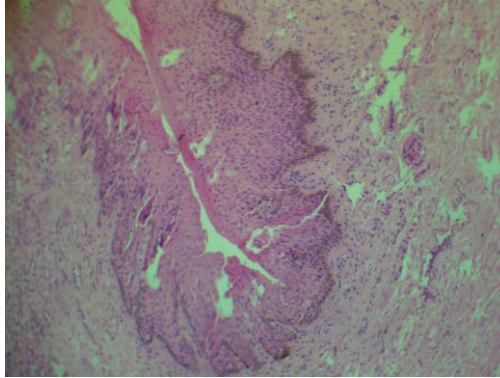
Patient Name	Ms. SHOKEY JAN/ANZWALA	Client Name	Apex Medicare, Jammu & Kashmir	Specimen Received	23/02/2020
Age/Sex	24YRS/F			Specimen Type	Tissue
Patient ID	012002220336			Collection Date	23/02/2020
Specimen ID	MOLQ/B-418/2020			Report Date	25/02/2020

SURGICAL PATHOLOGY REPORT

Anal fissure

DIAGNOSIS

NON SPECIFIC INFLAMMATION



SPECIMEN

Anal fissure

GROSS

Received autolyzed 1x1.5cm grayish white tissue piece.(E/A)

Microscopy

Section examined shows squamous lining epithelium with fibrocollageneous tissue, blood vessels and inflammatory cells.

No granuloma seen. No malignant cells seen.

Note : All biopsy specimen will be stored for 15 (fifteen)days, block and slides for 5(five) years only from the time of receipt at the laboratory. No request ,for any of the above ,will be entertained after the due date.

Reference

- i) Rosai and Ackerman's Surgical Pathology.
- ii) Modern Surgical Pathology.

Gulshan Yadav, MD
Consultant Pathologist