

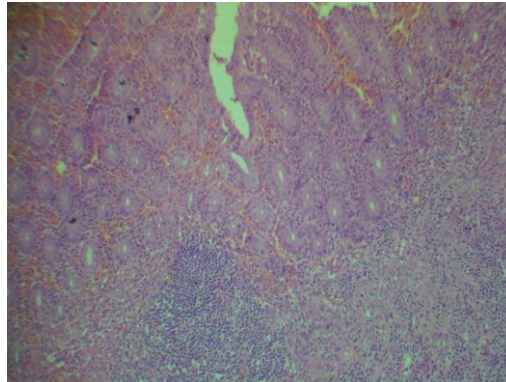
<b>Patient Name</b>	Mr. VANSHIT BANSAL	<b>Client Name</b>	Goyal Nursing Home, Palwal	<b>Specimen Received</b>	22/02/2020
<b>Age/Sex</b>	17YRS/M			<b>Specimen Type</b>	Tissue
<b>Patient ID</b>	012002220187			<b>Collection Date</b>	22/02/2020
<b>Specimen ID</b>	MOLQ/B-412/2020			<b>Report Date</b>	25/02/2020

## SURGICAL PATHOLOGY REPORT

### Appendix

#### DIAGNOSIS

#### ACUTE APPENDICITIS



#### **SPECIMEN**

Appendix

#### **GROSS**

Received 5x2cm long appendix. Cut section shows fecolith.

#### **Microscopy**

Section examined shows lymphoid follicles with ulcerative mucosa. Deeper tissue shows inflammatory cells (polymorphs and lymphocytes). No granuloma seen. No malignant cells seen.

**Note :** All biopsy specimen will be stored for 15 (fifteen) days, block and slides for 5 (five) years only from the time of receipt at the laboratory. No request, for any of the above, will be entertained after the due date.

#### **Reference**

- i) Rosai and Ackerman's Surgical Pathology.
- ii) Modern Surgical Pathology.

**Gulshan Yadav, MD**  
Consultant Pathologist