

**Patient Name** Ms. BASANTI  
**Age/Sex** 37YRS/F  
**Patient ID** 012002220171  
**Specimen ID** MOLQ/B-411/2020

**Client Name** Kriti Hospital

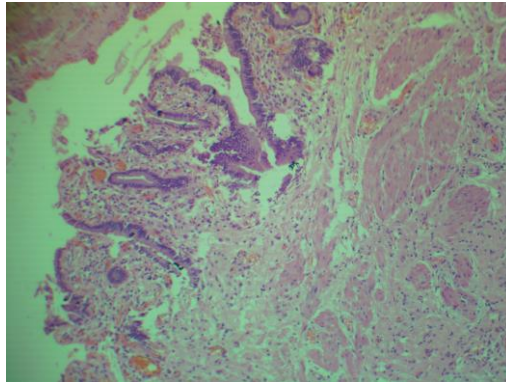
**Specimen Received** 22/02/2020  
**Specimen Type** Tissue  
**Collection Date** 22/02/2020  
**Report Date** 25/02/2020

## SURGICAL PATHOLOGY REPORT

### Gall Bladder

#### DIAGNOSIS

**CHOLECYSTITIS.**



#### SPECIMEN

Gall Bladder

#### GROSS

Received 9.8x2.2cm long gall bladder. Cut section shows no stones. Wall thickness 0.7mm.


#### Microscopy

Section examined shows ulcerative mucosa and Rokitansky-Aschoff sinuses (irregularly shaped tubular structures lined by cuboidal lining epithelium with round to oval nucleus) with fibrocollagenous tissue and inflammatory cells (lymphocytes).

**Note :** All biopsy specimen will be stored for 15 (fifteen) days, block and slides for 5 (five) years only from the time of receipt at the laboratory. No request, for any of the above, will be entertained after the due date.

#### Reference

- i) Rosai and Ackerman's Surgical Pathology.
- ii) Modern Surgical Pathology.

  
**Gulshan Yadav, MD**  
Consultant Pathologist