

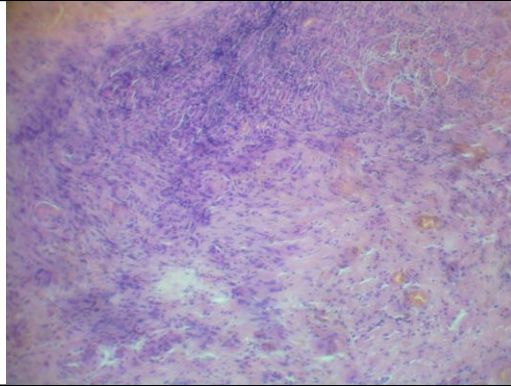
Patient Name	Mr. LOKESH	Client Name	Wry Rajeev Hospital	Specimen Received	17/02/2020
Age/Sex	22YRS/M			Specimen Type	Tissue
Patient ID	012002170266			Collection Date	17/02/2020
Specimen ID	MOLQ/B-361-20			Report Date	26/02/2020

SURGICAL PATHOLOGY REPORT

Right Soul (Foot)

DIAGNOSIS

INFLAMMATORY LESION WITH GRANULATION TISSUE.



SPECIMEN

Right Soul (Foot)

GROSS

Received 1x1 cm grayish white tissue piece.


Microscopy

1. Section examined shows fibrin and myxomatous changes along with blood vessels, inflammatory cells (polymorphs, lymphocytes) with occasional histiocytes.
2. No granuloma seen. No malignant cells seen.

Note : All biopsy specimen will be stored for 15 (fifteen) days, block and slides for 5 (five) years only from the time of receipt at the laboratory. No request, for any of the above, will be entertained after the due date.

Reference

- i) Rosai and Ackerman's Surgical Pathology.
- ii) Modern Surgical Pathology.


Gulshan Yadav, MD
Consultant Pathologist