

Patient Name Mr. NISAR AHMMAD
Age/Sex 42YRS/M
Patient ID 012002210336
Specimen ID MOLQ/B-410/2020

Client Name Apex Medicare, Jammu & Kashmir

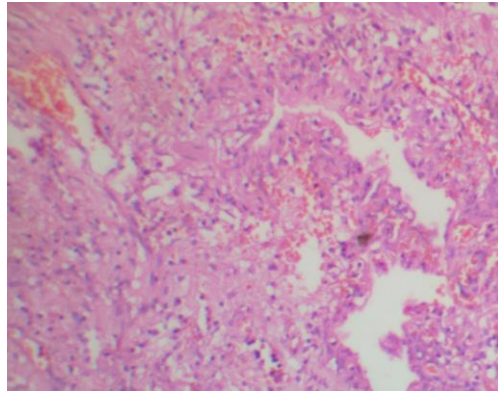
Specimen Received 21/02/2020
Specimen Type Tissue
Collection Date 21/02/2020
Report Date 24/02/2020

SURGICAL PATHOLOGY REPORT

Pile Mass

DIAGNOSIS

HEMORROIDS.



SPECIMEN

Pile Mass

GROSS

Received 2x2 cm greyish white tissue piece.


Microscopy

Section examined shows squamous lining epithelium with round to oval nucleus, submucosal glands (with mild anisonucleosis), fibro collagenous tissue with blood vessels. No granuloma and no malignant cells seen.

Note : All biopsy specimen will be stored for 15 (fifteen)days, block and slides for 5(five) years only from the time of receipt at the laboratory. No request ,for any of the above ,will be entertained after the due date.

Reference

- i) Rosai and Ackerman's Surgical Pathology.
- ii) Modern Surgical Pathology.


Gulshan Yadav, MD
Consultant Pathologist