

Patient Name Ms. SABEENA
Age/Sex 29YRS/F
Patient ID 012002210334
Specimen ID MOLQ/B-408/2020

Client Name Apex Medicare, Jammu &
Kashmir

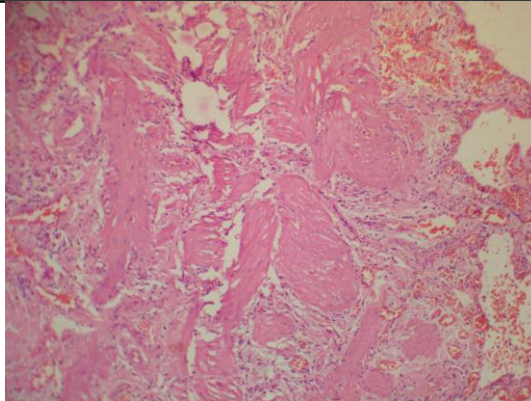
Specimen Received 21/02/2020
Specimen Type Tissue
Collection Date 21/02/2020
Report Date 24/02/2020

SURGICAL PATHOLOGY REPORT

Gall Bladder

DIAGNOSIS

CHOLECYSTITIS.



SPECIMEN

Gall Bladder

GROSS

Received 6.2x2.3cm long gall bladder, cut section shows no stones.


Microscopy

Section examined shows ulcerative mucosa and Rokitansky-Aschoff sinus (irregularly shaped tubular structures lined by cuboidal lining epithelium with round to oval nucleus) with fibrocollagenous tissue and inflammatory cells (lymphocytes).

Note : All biopsy specimen will be stored for 15 (fifteen) days, block and slides for 5 (five) years only from the time of receipt at the laboratory. No request, for any of the above, will be entertained after the due date.

Reference

- i) Rosai and Ackerman's Surgical Pathology.
- ii) Modern Surgical Pathology.


Gulshan Yadav, MD
Consultant Pathologist