

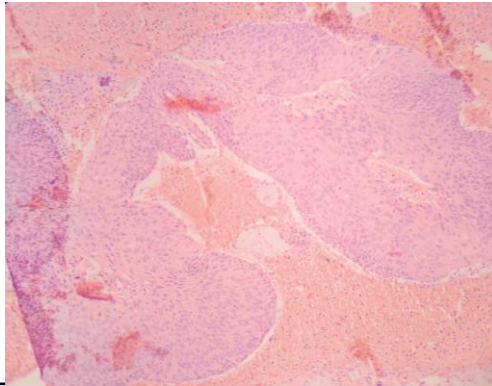
Patient Name	Mrs. DEVKI	Client Name	Sona Devi Hospital	Specimen Received	14/02/2020
Age/Sex	55YRS/F			Specimen Type	Tissue
Patient ID	012002140240			Collection Date	14/02/2020
Specimen ID	MOLQ/B-327-20			Report Date	25/02/2020

SURGICAL PATHOLOGY REPORT

Endometrial Biopsy

DIAGNOSIS

Suggestive of Metastatic Squamous Cell Carcinoma- Moderately Differentiated



SPECIMEN

Endometrial Biopsy

GROSS

Received multiple grayish white tissue piece.

Microscopy

Sections show hemorrhagic tissue with presence of nests and sheets of squamous epithelium with loss of polarity of cells and anaplasia. Squamous cells have enlarged nuclei with pleomorphism and hyperchromasia. Intracellular keratinisation seen. Inflammatory infiltrate seen in surrounding tissue.

Note : All biopsy specimen will be stored for 15 (fifteen)days, block and slides for 5(five) years only from the time of receipt at the laboratory. No request ,for any of the above ,will be entertained after the due date.

Reference

- i) Rosai and Ackerman's Surgical Pathology.
- ii) Modern Surgical Pathology.

Gulshan Yadav, MD
Consultant Pathologist