

Patient Name Mrs. NEELAM
Age/Sex 30YRS/F
Patient ID 092002200042
Specimen ID MOLQ/B-393/2020

Client Name Civil Hospital Sec-10

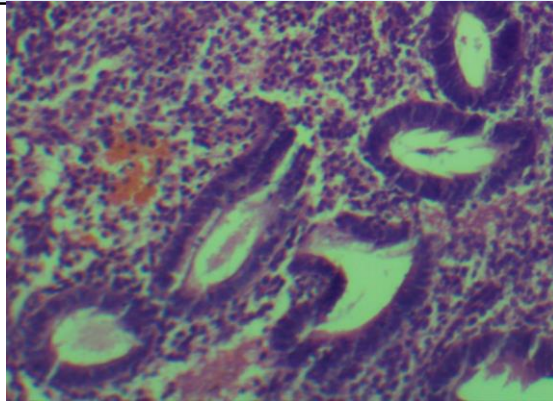
Specimen Received 20/02/2020
Specimen Type Tissue
Collection Date 20/02/2020
Report Date 24/02/2020

SURGICAL PATHOLOGY REPORT

Endometrium

DIAGNOSIS

PROLIFERATIVE PHASE



SPECIMEN

Endometrium

GROSS

Received multiple grayish white tissue piece.

Microscopy


Section examined shows small endometrial glands with cuboidal to columnar lining with small round to oval nucleus with squamous metaplasia and few glands. Stroma shows mononuclear inflammatory cells.

No granuloma seen. No malignant cells seen.

Note : All biopsy specimen will be stored for 15 (fifteen) days, block and slides for 5 (five) years only from the time of receipt at the laboratory. No request, for any of the above, will be entertained after the due date.

Reference

- i) Rosai and Ackerman's Surgical Pathology.
- ii) Modern Surgical Pathology.


Gulshan Yadav, MD
Consultant Pathologist