

Patient Name Mrs. LALITA
Age/Sex 30YRS/F
Patient ID 012002200229
Specimen ID MOLQ/B-397/2020

Client Name Expert Healthcare Centre

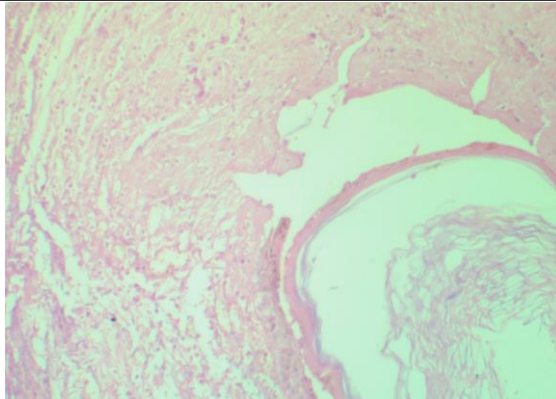
Specimen Received 20/02/2020
Specimen Type Tissue
Collection Date 20/02/2020
Report Date 24/02/2020

SURGICAL PATHOLOGY REPORT

Swelling Left Thigh

DIAGNOSIS

EPIDERMAL CYST.



SPECIMEN

Swelling Left Thigh

GROSS

Received 2.1x2.1cm long cystic tissue piece. Cut section shows cheesy material.

Microscopy


Section examined shows squamous lining epithelium with round to oval nucleus, mature adipose cells and keratin flakes.

No granuloma seen. No malignant cells seen.

Note : All biopsy specimen will be stored for 15 (fifteen)days, block and slides for 5(five) years only from the time of receipt at the laboratory. No request ,for any of the above ,will be entertained after the due date.

Reference

- i) Rosai and Ackerman's Surgical Pathology.
- ii) Modern Surgical Pathology.


Gulshan Yadav, MD
Consultant Pathologist