

Patient Name Ms. JHUMPA
Age/Sex 25YRS/F
Patient ID 012002200196
Specimen ID MOLQ/B-395/2020

Client Name Kriti Hospital

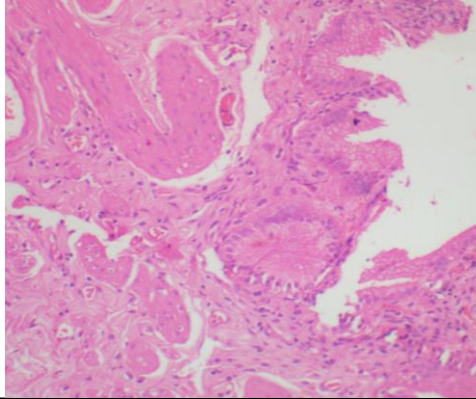
Specimen Received 20/02/2020
Specimen Type Tissue
Collection Date 20/02/2020
Report Date 24/02/2020

SURGICAL PATHOLOGY REPORT

Gall Bladder

DIAGNOSIS

CHOLECYSTITIS



SPECIMEN

Gall Bladder

GROSS

Received 8x3.1cm long gall bladder already cut open no stones. Wall thickness 0.9mm.


Microscopy

Section examined shows ulcerative mucosa and Rokitansky-Aschoff sinuses (irregularly shaped tubular structures lined by cuboidal lining epithelium with round to oval nucleus) with fibrocollagenous tissue and inflammatory cells (lymphocytes). section also shows hepatocytes.

Note : All biopsy specimen will be stored for 15 (fifteen) days, block and slides for 5 (five) years only from the time of receipt at the laboratory. No request, for any of the above, will be entertained after the due date.

Reference

- i) Rosai and Ackerman's Surgical Pathology.
- ii) Modern Surgical Pathology.


Gulshan Yadav, MD
Consultant Pathologist