

Patient Name Mr. Fayaz Ahmad
Age/Sex 40 YRS/M
Patient ID 012002140322
Specimen ID MOLQ/B-327-20

Client Name Apex Medicare, Jammu & Kashmir

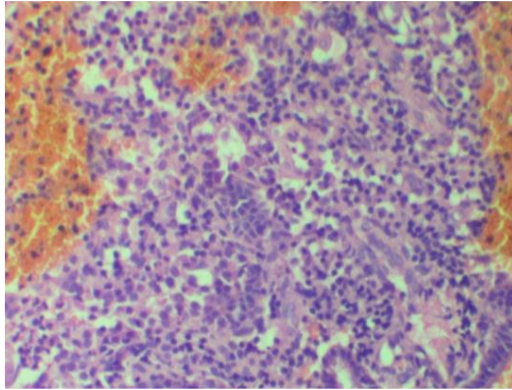
Specimen Received 14/02/2020
Specimen Type Tissue
Collection Date 14/02/2020
Report Date 20/02/2020

SURGICAL PATHOLOGY REPORT

Gall Bladder

DIAGNOSIS

CHOLECYSTITIS WITH POLYP.



SPECIMEN

Gall Bladder

GROSS

Received 5.1x2.3 cm long gall bladder already cut open without stones. Cut section shows 0.5x0.5 cm polyp.


Microscopy

Section examined shows polyp with squamous lining epithelium and inflammatory cells. Section also shows ulcerative mucosa and Rokitansky Aschoff sinus (irregularly shaped tubular structures lined by cuboidal lining epithelium with round to oval nucleus) with fibro collagenous tissue and inflammatory cells (lymphocytes).

Note : All biopsy specimen will be stored for 15 (fifteen) days, block and slides for 5 (five) years only from the time of receipt at the laboratory. No request, for any of the above, will be entertained after the due date.

Reference

- i) Rosai and Ackerman's Surgical Pathology.
- ii) Modern Surgical Pathology.


Gulshan Yadav, MD
Consultant Pathologist