

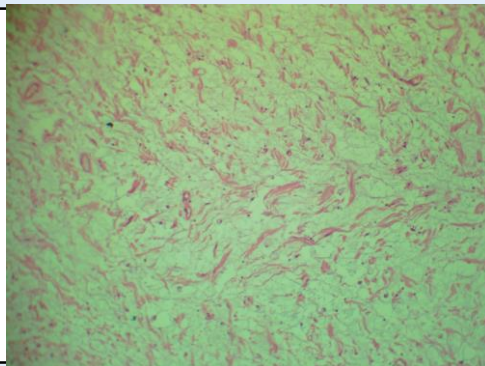
Patient Name	Mr. UMER/ZEWAN	Client Name	A-One Collection Centre, Jammu & Kashmir	Specimen Received	19-Feb-2020
Age/Sex	22YRS/M			Specimen Type	Tissue
Patient ID	042002180020			Collection Date	19-Feb-2020
Specimen ID	MOLQ/B-372-20			Report Date	23-Feb-2020

SURGICAL PATHOLOGY REPORT

Fibrolipoma Right Thigh

DIAGNOSIS

BENIGN MESENCHYMAL LESION



SPECIMEN

Fibrolipoma Right Thigh

GROSS

Received 2x1 cm grayish white tissue piece. E/A

Microscopy

Section examined shows fibrocollagenous tissue with myxomatous changes, nerve bundles, muscle bundles and blood vessels.

No granuloma seen. No malignant cells seen.

Note : All biopsy specimen will be stored for 15 (fifteen) days, block and slides for 5 (five) years only from the time of receipt at the laboratory. No request, for any of the above, will be entertained after the due date.

Reference

- i) Rosai and Ackerman's Surgical Pathology.
- ii) Modern Surgical Pathology.

Gulshan Yadav, MD
Consultant Pathologist