

Patient Name Mr. AHMAD
Age/Sex 35YRS/M
Patient ID 012002190402
Specimen ID MOLQ/B-385-20

Client Name Apex Medicare, Jammu &
Kashmir

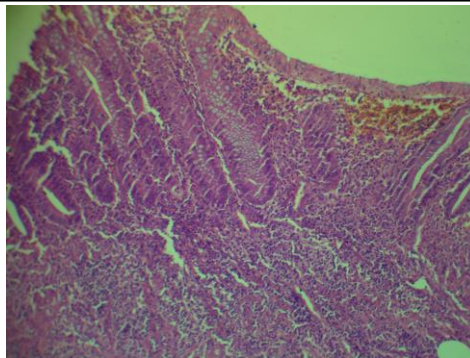
Specimen Received 19-Feb-2020
Specimen Type Tissue
Collection Date 19-Feb-2020
Report Date 23-Feb-2020

SURGICAL PATHOLOGY REPORT

Acute Appendicitis

DIAGNOSIS

ACUTE APPENDICITIS



SPECIMEN

Acute Appendicitis

GROSS

Received 5.1x2.3 cm long appendix with mesoappendix.
Cut section shows feco-lith.

Microscopy

Section examined shows lymphoid follicles with ulcerative mucosa. Deeper tissue shows inflammatory cells (polymorphs and lymphocytes). No granuloma seen. No malignant cells seen.

Note : All biopsy specimen will be stored for 15 (fifteen)days, block and slides for 5(five) years only from the time of receipt at the laboratory. No request ,for any of the above ,will be entertained after the due date.

Reference

- i) Rosai and Ackerman's Surgical Pathology.
- ii) Modern Surgical Pathology.

Gulshan Yadav, MD
Consultant Pathologist