

Patient Name Ms. SUNIL
Age/Sex 54YRS/F
Patient ID 012002190316
Specimen ID MOLQ/B-392-20

Client Name Pushpanjali Hospital (Rewari)

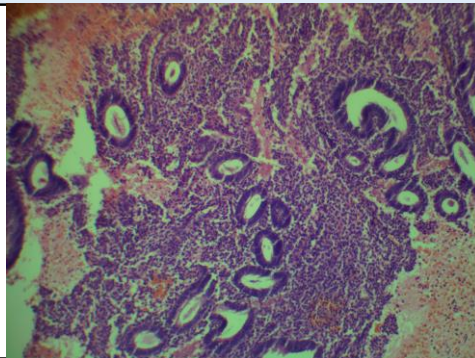
Specimen Received 19-Feb-2020
Specimen Type Tissue
Collection Date 19-Feb-2020
Report Date 23-Feb-2020

SURGICAL PATHOLOGY REPORT

Endometrial Biopsy (Thickened)

DIAGNOSIS

SIMPLE HYPERPLASIA WITHOUT ATYPIA



SPECIMEN

Endometrial Biopsy (Thickened)

GROSS

Received multiple grayish white tissue piece.

Microscopy

Section examined shows small and cystically dilated endometrial glands with cuboidal to columnar lining with small round nucleus. Stroma shows mononuclear inflammatory cells.

No granuloma seen. No malignant cells seen.

Note : All biopsy specimen will be stored for 15 (fifteen)days, block and slides for 5(five) years only from the time of receipt at the laboratory. No request ,for any of the above ,will be entertained after the due date.

Reference

- i) Rosai and Ackerman's Surgical Pathology.
- ii) Modern Surgical Pathology.

Gulshan Yadav, MD
Consultant Pathologist