

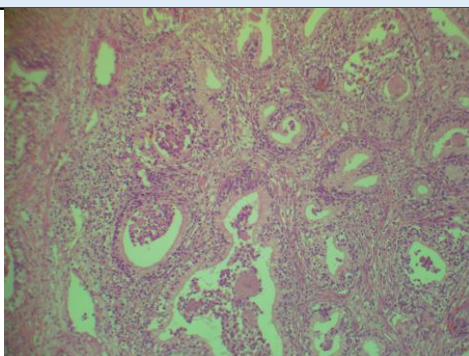
<b>Patient Name</b>	<b>Mr. SOVRAN SINGH</b>	<b>Client Name</b> Uttam Diagnostics, Agra	<b>Specimen Received</b>	<b>19-Feb-2020</b>
<b>Age/Sex</b>	70 Years/Male		<b>Specimen Type</b>	Tissue
<b>Patient ID</b>	012002190050		<b>Collection Date</b>	19-Feb-2020
<b>Specimen ID</b>	MOLQ/B-388-20		<b>Report Date</b>	23-Feb-2020

## SURGICAL PATHOLOGY REPORT

### TURP Chips

#### DIAGNOSIS

### BENIGN PROSTATIC HYPERPLASIA



#### SPECIMEN

TURP Chips

#### GROSS

Received multiple grayish white tissue piece, 4X4 cm in aggregate.

#### Microscopy

Section examined shows bilayered prostatic glands with columnar lining epithelium and with small round to oval nucleus surrounded by large number of fibrocollagenous tissue and mononuclear inflammatory cell.

No granuloma seen. No malignant cells seen.

**Note :** All biopsy specimen will be stored for 15 (fifteen)days, block and slides for 5(five) years only from the time of receipt at the laboratory. No request ,for any of the above ,will be entertained after the due date.

#### Reference

- i) Rosai and Ackerman's Surgical Pathology.
- ii) Modern Surgical Pathology.

**Gulshan Yadav, MD**  
Consultant Pathologist