

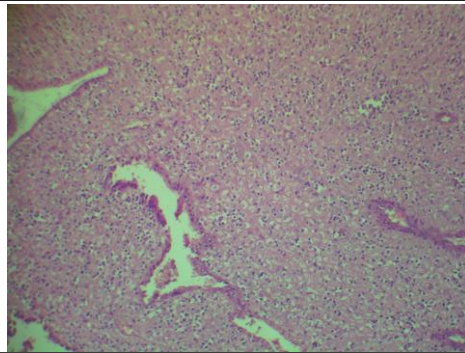
Patient Name	Mrs. SHALINI AGARWAL	Client Name	Lifeaid Wellness Centre	Specimen Received	17-Feb-2020
Age/Sex	45YRS/F			Specimen Type	Tissue
Patient ID	012002170183			Collection Date	17-Feb-2020
Specimen ID	MOLQ/B-356-20			Report Date	23-Feb-2020

SURGICAL PATHOLOGY REPORT

Uterus with Right Ovarian Cyst

DIAGNOSIS

LEIOMYOMA WITH SIMPLE HYPERPLASIA WITHOUT ATYPIA



SPECIMEN

Uterus with Right Ovarian Cyst

GROSS

Received 13x8 cm uterus with cervix already cut open with unilateral adnexa. Ovary size 4x5 cm (cut section shows multiloculated cyst). Cut section shows fibroid measuring 2x2 cm. Endometrium is thickened.

Microscopy

Section examined shows

- 1) Endometrium with simple hyperplasia without atypia, cystically dilated glands, decidual cells. Stroma shows mononuclear inflammatory cells
- 2) Myometrium is unremarkable
- 3) Cervix with mononuclear inflammatory cells
- 4) Ovary with simple cyst and tube unremarkable
- 5) Fibroid with interlacing muscle bundles

Note : All biopsy specimen will be stored for 15 (fifteen) days, block and slides for 5 (five) years only from the time of receipt at the laboratory. No request, for any of the above, will be entertained after the due date.

Reference

- i) Rosai and Ackerman's Surgical Pathology.
- ii) Modern Surgical Pathology.

Gulshan Yadav, MD
Consultant Pathologist