

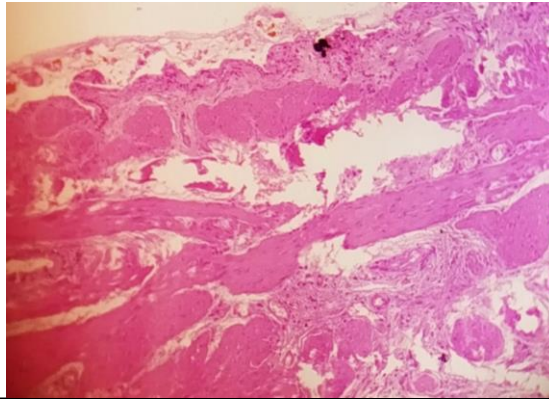
Patient Name	Mrs. PHOOL PATI	Client Name	S. M. Diagnostics, Kaithal	Specimen Received	19/02/2020
Age/Sex	73YRS/F			Specimen Type	Tissue
Patient ID	012002190015			Collection Date	19/02/2020
Specimen ID	MOLQ/B-383/2020			Report Date	22/02/2020

SURGICAL PATHOLOGY REPORT

Gall Bladder

DIAGNOSIS

CHOLECYSTITIS AND CHOLELITHIASIS.



SPECIMEN

Gall Bladder

GROSS

Received 8x2.3cm long gall bladder already cut open stones. Wall thickness 0.3mm.


Microscopy

Section examined shows ulcerative mucosa and Rokitansky-Aschoff sinus (irregularly shaped tubular structures lined by cuboidal lining epithelium with round to oval nucleus) with fibrocollagenous tissue and inflammatory cells (lymphocytes).

Note : All biopsy specimen will be stored for 15 (fifteen) days, block and slides for 5 (five) years only from the time of receipt at the laboratory. No request, for any of the above, will be entertained after the due date.

Reference

- i) Rosai and Ackerman's Surgical Pathology.
- ii) Modern Surgical Pathology.


Gulshan Yadav, MD
Consultant Pathologist