

Patient Name FATIAM R/O ZANIPORA
Age/Sex 45 YRS/F
Patient ID 012002180077
Specimen ID MOLQ/B-379/2020

Client Name Apex Medicare, Jammu &
Kashmir

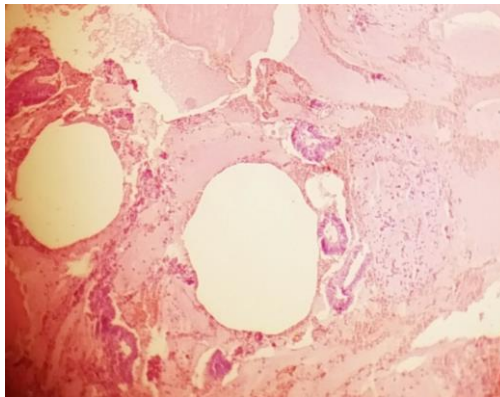
Specimen Received 19/02/2020
Specimen Type Tissue
Collection Date 19/02/2020
Report Date 22/02/2020

SURGICAL PATHOLOGY REPORT

Endometrium

DIAGNOSIS

PROLIFERATIVE PHASE



SPECIMEN

Endometrium

GROSS

Received multiple grayish white tissue piece.


Microscopy

Section examined shows small endometrial glands with cuboidal lining with small round nucleus. Stroma shows mononuclear inflammatory cells. No granuloma seen. No malignant cells seen.

Note : All biopsy specimen will be stored for 15 (fifteen) days, block and slides for 5 (five) years only from the time of receipt at the laboratory. No request, for any of the above, will be entertained after the due date.

Reference

- i) Rosai and Ackerman's Surgical Pathology.
- ii) Modern Surgical Pathology.


Gulshan Yadav, MD
Consultant Pathologist