

Patient Name FEROZ AHMAD R/O
MATTAN
Age/Sex 36 YRS/M
Patient ID 012002180075
Specimen ID MOLQ/B-377/2020

Client Name Apex Medicare, Jammu &
Kashmir

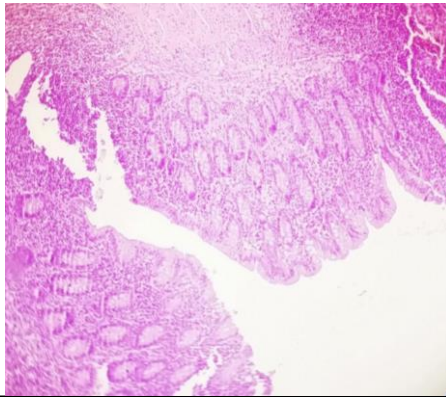
Specimen Received 19/02/2020
Specimen Type Tissue
Collection Date 19/02/2020
Report Date 22/02/2020

SURGICAL PATHOLOGY REPORT

Appendix

DIAGNOSIS

ACUTE APPENDICITIS



SPECIMEN

Appendix

GROSS

Received 7x1cm long appendix. Cut section shows fecolith.


Microscopy

Section examined shows lymphoid follicles with ulcerative mucosa. Deeper tissue shows inflammatory cells (polymorphs and lymphocytes). No granuloma seen. No malignant cells seen.

Note : All biopsy specimen will be stored for 15 (fifteen)days, block and slides for 5(five) years only from the time of receipt at the laboratory. No request ,for any of the above ,will be entertained after the due date.

Reference

- i) Rosai and Ackerman's Surgical Pathology.
- ii) Modern Surgical Pathology.


Gulshan Yadav, MD
Consultant Pathologist