

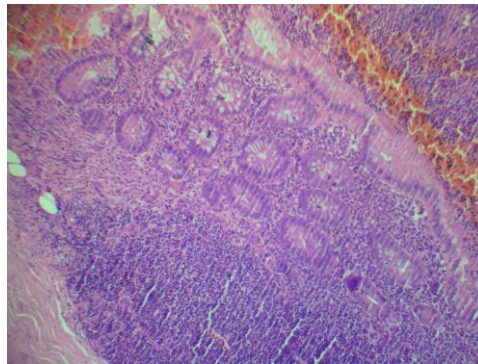
Patient Name	Master. DEVANSH PANDEY	Client Name	Goyal Nursing Home, Palwal	Specimen Received	17-Feb-2020
Age/Sex	11YRS/M			Specimen Type	Tissue
Patient ID	012002170240			Collection Date	17-Feb-2020
Specimen ID	MOLQ/B-358/2020			Report Date	21-Feb-2020

SURGICAL PATHOLOGY REPORT

Appendix

DIAGNOSIS

ACUTE APPENDICITIS



SPECIMEN

Appendix

GROSS

Received 4.8x1.2cm long appendix. Cut section shows feco-lith.

Microscopy

Section examined shows lymphoid follicles with ulcerative mucosa. Deeper tissue shows inflammatory cells (polymorphs and lymphocytes). No granuloma seen. No malignant cells seen.

Note : All biopsy specimen will be stored for 15 (fifteen)days, block and slides for 5(five) years only from the time of receipt at the laboratory. No request ,for any of the above ,will be entertained after the due date.

Reference

- i) Rosai and Ackerman's Surgical Pathology.
- ii) Modern Surgical Pathology.

Gulshan Yadav, MD
Consultant Pathologist