

**Patient Name** Baby. SANDHYA  
**Age/Sex** 11YRS/F  
**Patient ID** 012002170239  
**Specimen ID** MOLQ/B-357/2020

**Client Name** Goyal Nursing Home, Palwal

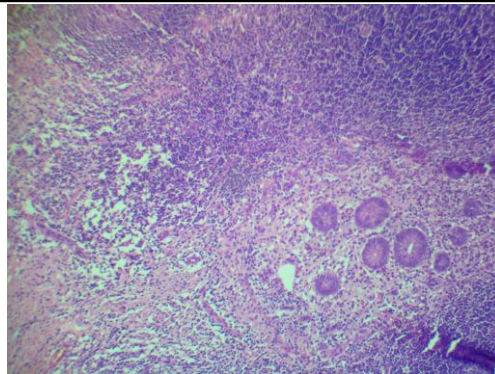
**Specimen Received** 17-Feb-2020  
**Specimen Type** Tissue  
**Collection Date** 17-Feb-2020  
**Report Date** 21-Feb-2020

## SURGICAL PATHOLOGY REPORT

### Appendix

#### DIAGNOSIS

#### ACUTE APPENDICITIS



#### SPECIMEN

Appendix

#### GROSS

Received 6.8x1.9cm long appendix. Cut section shows feco-lith.

#### Microscopy

Section examined shows lymphoid follicles with ulcerative mucosa. Deeper tissue shows inflammatory cells (polymorphs and lymphocytes). No granuloma seen. No malignant cells seen.

**Note :** All biopsy specimen will be stored for 15 (fifteen)days, block and slides for 5(five) years only from the time of receipt at the laboratory. No request ,for any of the above ,will be entertained after the due date.

#### Reference

- i) Rosai and Ackerman's Surgical Pathology.
- ii) Modern Surgical Pathology.

A handwritten signature in black ink, appearing to read 'Gulshan'.

**Gulshan Yadav, MD**  
**Consultant Pathologist**