

Patient Name Ms. SHAHEENA
Age/Sex 52YRS/F
Patient ID 012002160033
Specimen ID MOLQ/B-348-20

Client Name Apex Medicare, Jammu & Kashmir

Specimen Received 16-Feb-2020
Specimen Type Tissue
Collection Date 16-Feb-2020
Report Date 21-Feb-2020

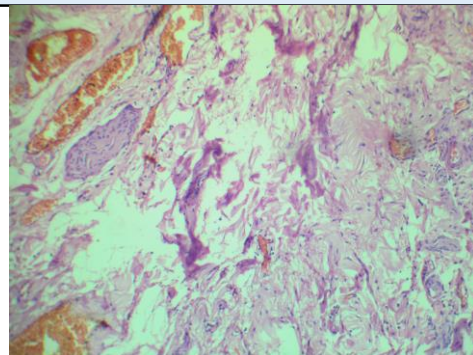
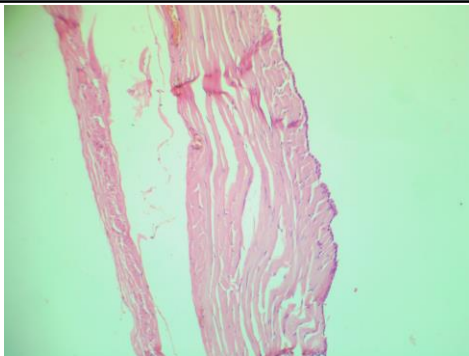SURGICAL PATHOLOGY REPORT

Right Ovarian Cyst, Cholecystectomy

DIAGNOSIS

A) SIMPLE CYST (RIGHT OVARY)

B) CHOLECYSTITIS AND CHOLELITHIASIS



SPECIMEN

Right Ovarian Cyst, Cholecystectomy

GROSS

Received 4.3x3.5 cm cystic tissue piece, cut section shows clear fluid, uniloculated.

Received 6.9x2.9 cm long gall bladder. Cut section shows stones. Wall Thickness 0.4 mm.

Both received in a single container.

Microscopy

A) Section examined shows ovarian tissue with cuboidal lining epithelium with round to oval nucleus.

No granuloma seen. No malignant cells seen.

B) Section examined shows ulcerative mucosa and Rokitansky Aschoff sinus (irregularly shaped tubular structures lined by cuboidal lining epithelium with round to oval nucleus) with fibrocollagenous tissue and inflammatory cells (lymphocytes).

Note : All biopsy specimen will be stored for 15 (fifteen) days, block and slides for 5 (five) years only from the time of receipt at the laboratory. No request, for any of the above, will be entertained after the due date.

Reference

- i) Rosai and Ackerman's Surgical Pathology.
- ii) Modern Surgical Pathology.



Gulshan Yadav, MD
Consultant Pathologist