

Patient Name Mr. SUNIL KUMAR
Age/Sex 47YRS/M
Patient ID 012002150158
Specimen ID MOLQ/B-336/2020

Client Name Sona Devi Hospital

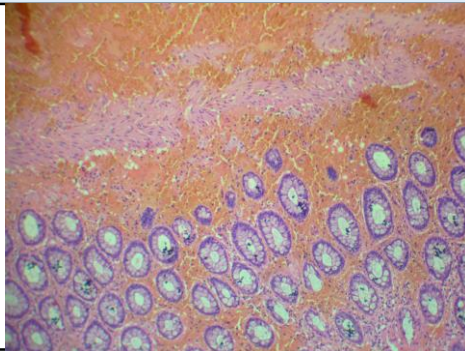
Specimen Received 15-Feb-2020
Specimen Type Tissue
Collection Date 15-Feb-2020
Report Date 20-Feb-2020

SURGICAL PATHOLOGY REPORT

Hemorrhoids

DIAGNOSIS

HEMORROIDS



SPECIMEN

Hemorrhoids

GROSS

Received 4x2.8cm greyish white tissue piece.


Microscopy

Section examined shows submucosal glands with round to oval nucleus and blood vessels with RBCs. No granuloma and no malignant cells seen.

Note : All biopsy specimen will be stored for 15 (fifteen)days, block and slides for 5(five) years only from the time of receipt at the laboratory. No request ,for any of the above ,will be entertained after the due date.

Reference

- i) Rosai and Ackerman's Surgical Pathology.
- ii) Modern Surgical Pathology.



Gulshan Yadav, MD
Consultant Pathologist