

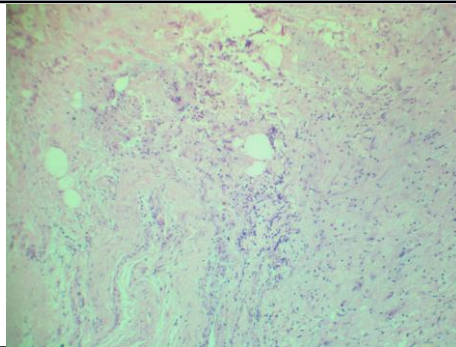
<b>Patient Name</b>	Mr. GH NABI GAMI/RAMIPORA	<b>Specimen Received</b>	14-Feb-2020
<b>Age/Sex</b>	42YRS/M	<b>Specimen Type</b>	Tissue
<b>Patient ID</b>	012002140323	<b>Collection Date</b>	14-Feb-2020
<b>Specimen ID</b>	MOLQ/B-330-20	<b>Report Date</b>	18-Feb-2020
	<b>Client Name</b> Apex Medicare, Jammu & Kashmir		

## SURGICAL PATHOLOGY REPORT

### Umbilical Biopsy

#### DIAGNOSIS

**UMBILICAL SINUS WITH ACUTE INFLAMMATION.**



#### **SPECIMEN**

Umbilical Biopsy

#### **GROSS**

Received 4x3 cm grayish white tissue piece.

#### **Microscopy**

Section examined shows squamous lining epithelium with hyperkeratosis, parakeratosis. Deeper tissue shows fibrocollagenous tissue with inflammatory cells (polymorphs, lymphocytes).

No granuloma seen. No malignant cells seen.

**Note :** All biopsy specimen will be stored for 15 (fifteen)days, block and slides for 5(five) years only from the time of receipt at the laboratory. No request ,for any of the above ,will be entertained after the due date.

#### **Reference**

- i) Rosai and Ackerman's Surgical Pathology.
- ii) Modern Surgical Pathology.

**Gulshan Yadav, MD**  
Consultant Pathologist