

Patient Name Mr. JAHID
Age/Sex 29YRS/M
Patient ID 012002140205
Specimen ID MOLQ/B-325-20

Client Name Family Hospital and Surgical
Centre

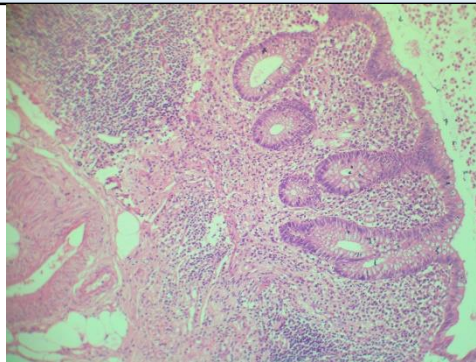
Specimen Received 14-Feb-2020
Specimen Type Tissue
Collection Date 14-Feb-2020
Report Date 18-Feb-2020

SURGICAL PATHOLOGY REPORT

Acute Appendix

DIAGNOSIS

ACUTE APPENDICITIS



SPECIMEN

Acute Appendix

GROSS

Received 6.1x1.1 cm long appendix. Cut section shows feco-lith.

Microscopy

Section examined shows lymphoid follicles with ulcerative mucosa. Deeper tissue shows inflammatory cells (polymorphs and lymphocytes). No granuloma seen. No malignant cells seen.

Note : All biopsy specimen will be stored for 15 (fifteen)days, block and slides for 5(five) years only from the time of receipt at the laboratory. No request ,for any of the above ,will be entertained after the due date.

Reference

- i) Rosai and Ackerman's Surgical Pathology.
- ii) Modern Surgical Pathology.

A handwritten signature in black ink, appearing to read 'Gulshan', written over a light blue rectangular background.

Gulshan Yadav, MD
Consultant Pathologist