

Patient Name Mr. SATVEER
Age/Sex 30YRS/M
Patient ID 012002140181
Specimen ID MOLQ/B-324-20

Client Name Ashtha Path Lab-B

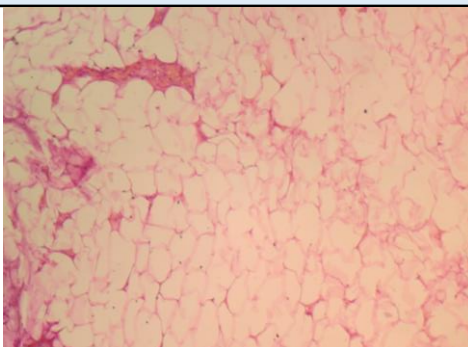
Specimen Received 14-Feb-2020
Specimen Type Tissue
Collection Date 14-Feb-2020
Report Date 18-Feb-2020

SURGICAL PATHOLOGY REPORT

Lipoma Left Arm

DIAGNOSIS

LIPOMA



SPECIMEN

Lipoma Left Arm

GROSS

Received 5x3 cm yellowish tissue piece.

Microscopy

Section examined shows mature adipose cells with few inflammatory cells.

No granuloma seen. No malignant cells seen.

Note : All biopsy specimen will be stored for 15 (fifteen)days, block and slides for 5(five) years only from the time of receipt at the laboratory. No request ,for any of the above ,will be entertained after the due date.

Reference

- i) Rosai and Ackerman's Surgical Pathology.
- ii) Modern Surgical Pathology.

Gulshan Yadav, MD
Consultant Pathologist