

Patient Name Mr. MOHD AFZAL BHAT
Age/Sex 53YRS/M
Patient ID 012002140041
Specimen ID MOLQ/B-320-20

Client Name Bandipora Collection Centre,
Jammu & Kashmir

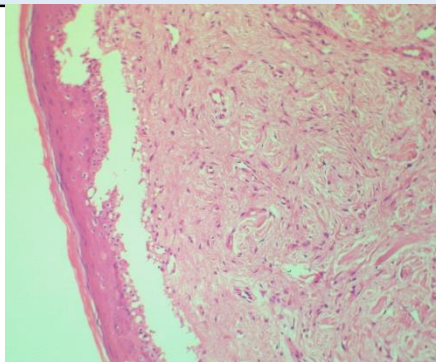
Specimen Received 14-Feb-2020
Specimen Type Tissue
Collection Date 14-Feb-2020
Report Date 18-Feb-2020

SURGICAL PATHOLOGY REPORT

Lower Lip

DIAGNOSIS

ORAL FIBROMA



SPECIMEN

Lower Lip

GROSS

Received 1x1 cm grayish white tissue piece.

Microscopy

Section examined shows atrophic (few areas with broad and short rete pegs) squamous lining epithelium with round to oval nucleus with flat interface. Deeper tissue shows bundles of collagen fibers interspersed with fibrocytes, blood vessels and few inflammatory cells.

No granuloma seen. No malignant cells seen.

Note : All biopsy specimen will be stored for 15 (fifteen)days, block and slides for 5(five) years only from the time of receipt at the laboratory. No request ,for any of the above ,will be entertained after the due date.

Reference

- i) Rosai and Ackerman's Surgical Pathology.
- ii) Modern Surgical Pathology.

Tina Bhardwaj, MDS
Consultant Oral Pathologist

Gulshan Yadav, MD
Consultant Pathologist