

**Patient Name** Ms. REKHA  
**Age/Sex** 41 YRS/F  
**Patient ID** 012002080278  
**Specimen ID** MOLQ/B-269-20

**Client Name** Malhotra Diagnostics

**Specimen Received** 8-Feb-2020  
**Specimen Type** Tissue  
**Collection Date** 8-Feb-2020  
**Report Date** 17-Feb-2020

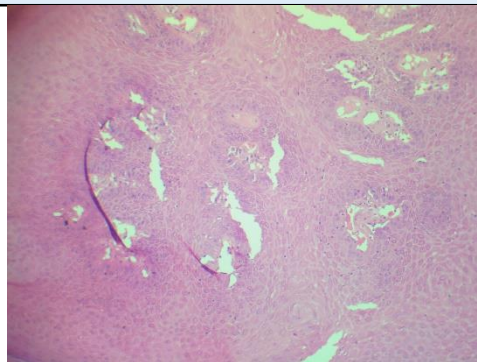
## SURGICAL PATHOLOGY REPORT

Buccal Mucosa (Side not mentioned)

### DIAGNOSIS

**BENIGN HYPERPLASTIC LESION.**

**Advised: Clinical co-relations.**



### SPECIMEN

Buccal Mucosa (Side not mentioned)

### GROSS

Received multiple tiny grayish white tissue piece..

### Microscopy

1. Section examined shows hyperplastic stratified squamous epithelium with round to oval nucleus.
2. Deeper tissue shows minimal connective tissue composed of fibrocollagenous tissue, blood vessels and few inflammatory cells.
3. No granuloma seen.
4. No malignant cells seen in the sample received.

**Note :** All biopsy specimen will be stored for 15 (fifteen)days, block and slides for 5(five) years only from the time of receipt at the laboratory. No request ,for any of the above ,will be entertained after the due date.

### Reference

- i) Rosai and Ackerman's Surgical Pathology.
- ii) Modern Surgical Pathology.



**Tina Bhardwaj, MDS**  
Consultant Oral Pathologist



**Gulshan Yadav, MD**  
Consultant Pathologist