

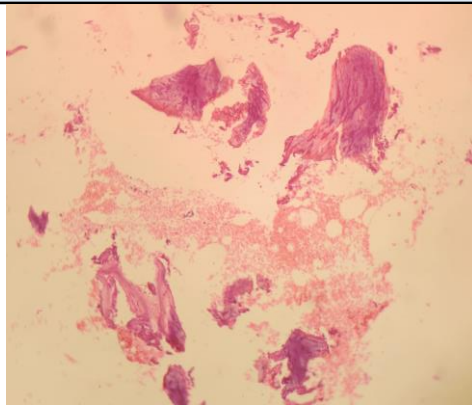
Patient Name	Ms. DILSHADA	Client Name	A-One Collection Centre,	Specimen Received	08-Feb-2020
Age/Sex	39 YRS/F		Jammu & Kashmir	Specimen Type	Tissue
Patient ID	042002080020			Collection Date	08-Feb-2020
Specimen ID	MOLQ/B-261/2020			Report Date	17-Feb-2020

SURGICAL PATHOLOGY REPORT

Lytic Lesion Right Medial Malleolus

DIAGNOSIS

KINDLY, CO-RELATE WITH CLINICAL AND RADIOLOGICAL FINDINGS.



SPECIMEN

Lytic Lesion Right Medial Malleolus

GROSS

Received multiple grayish white tissue piece.

Microscopy

1. Section examined shows calcified areas with fibrocollagenous tissue and RBCs.
2. No granuloma seen.
3. No malignant cells seen.

Note : All biopsy specimen will be stored for 15 (fifteen)days, block and slides for 5(five) years only from the time of receipt at the laboratory. No request ,for any of the above ,will be entertained after the due date.

Reference

- i) Rosai and Ackerman's Surgical Pathology.
- ii) Modern Surgical Pathology.

Gulshan Yadav, MD
Consultant Pathologist