

Patient Name Mrs. BABLI
Age/Sex 32 YRS/F
Patient ID 012002120157
Specimen ID MOLQ/B-296-20

Client Name Gobind Hospital

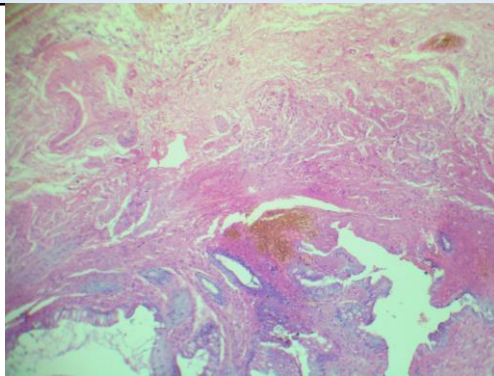
Specimen Received 12-Feb-2020
Specimen Type Tissue
Collection Date 12-Feb-2020
Report Date 17-Feb-2020

SURGICAL PATHOLOGY REPORT

Hemorrhoidectomy

DIAGNOSIS

HEMORROIDS



SPECIMEN

Hemorrhoidectomy

GROSS

Received 4x3 cm cm greyish white tissue piece.

Microscopy

Section examined shows mucosal lining epithelium with submucosal glands having small round nucleus. Deeper tissue shows glands with large number of blood vessels.

No granuloma and no malignant cells seen.

Note : All biopsy specimen will be stored for 15 (fifteen)days, block and slides for 5(five) years only from the time of receipt at the laboratory. No request ,for any of the above ,will be entertained after the due date.

Reference

- i) Rosai and Ackerman's Surgical Pathology.
- ii) Modern Surgical Pathology.

A handwritten signature in black ink, appearing to read 'Gulshan'.

Gulshan Yadav, MD
Consultant Pathologist