

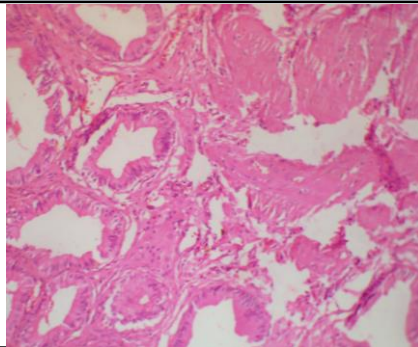
<b>Patient Name</b>	Mrs. SINDER KUMARI	<b>Client Name</b>	S. M. Diagnostics, Kaithal	<b>Specimen Received</b>	11-Feb-2020
<b>Age/Sex</b>	57 YRS/F			<b>Specimen Type</b>	Tissue
<b>Patient ID</b>	012002110003			<b>Collection Date</b>	11-Feb-2020
<b>Specimen ID</b>	MOLQ/B-282-20			<b>Report Date</b>	17-Feb-2020

## SURGICAL PATHOLOGY REPORT

### Gall Bladder

#### DIAGNOSIS

#### CHOLECYSTITIS



#### SPECIMEN

Gall Bladder

#### GROSS

Received autolyzed 9.4x3.6 cm long gall bladder. Cut section shows no stones.

#### Microscopy

Section examined shows autolytic changes with ulcerative mucosa and Rokitansky-Aschoff sinuses (irregularly shaped tubular structures lined by cuboidal lining epithelium with round to oval nucleus) with fibrocollagenous tissue and inflammatory cells (lymphocytes).

**Note :** All biopsy specimen will be stored for 15 (fifteen) days, block and slides for 5 (five) years only from the time of receipt at the laboratory. No request, for any of the above, will be entertained after the due date.

#### Reference

- i) Rosai and Ackerman's Surgical Pathology.
- ii) Modern Surgical Pathology.

**Gulshan Yadav, MD**  
Consultant Pathologist