

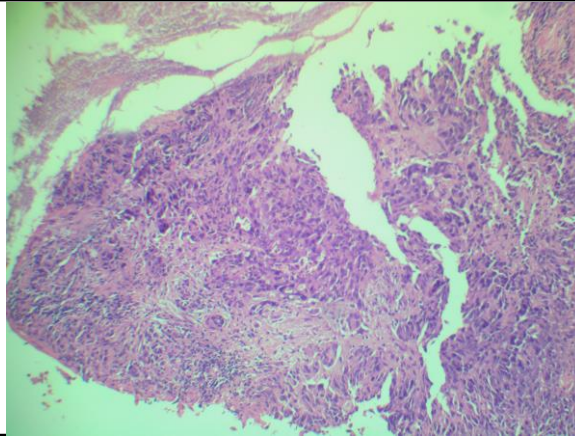
Patient Name	Mr. KISHAN LAL-48187	Specimen Received	10-Feb-2019
Age/Sex	93 Years/Male	Specimen Type	Tissue
Patient ID	012002100257	Client Name	Pushpanjali
Specimen ID	MOLQ/B-285/20	Hospital (Rewari)	Hospital (Rewari)
		Collection Date	10-Feb-2019
		Report Date	17-Feb-2019

SURGICAL PATHOLOGY REPORT

Bladder Tumor

DIAGNOSIS

HIGH GRADE UROTHELIAL CARCINOMA



SPECIMEN

Bladder Tumor

Microscopy

Histologic Type:

Tumor Configuration:

GROSS

Received multiple grayish white tissue piece, 1x1 cm in aggregate.

Urothelial (Transitional Cell) Carcinoma.

High Grade.

Solid / Nodule.

Adequacy of Material for Determining Muscularis Propria Invasion.

Muscularis Propria Invasion:

Invaded.

Lymph vascular Invasion:

Not Invaded.

Microscopic extent of tumor:

Tumor invaded subepithelial connective tissue (lamina propria).

Muscularis propria is invaded.

Dextrusor muscle not invaded

Note : All biopsy specimen will be stored for 15 (fifteen)days, block and slides for 5(five) years only from the time of receipt at the laboratory. No request ,for any of the above ,will be entertained after the due date.

Reference

- i) Rosai and Ackerman's Surgical Pathology.
- ii) Modern Surgical Pathology.

Gulshan Yadav, MD
Consultant Pathologist