

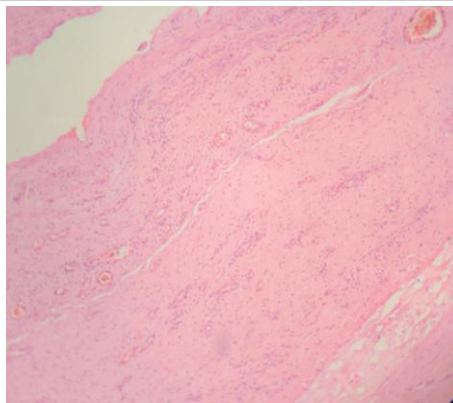
Patient Name	PRAVESH GAUTAM	Client Name	Sunrise Diagnostic Centre, Agra	Specimen Received	30-Jan-2020
Age/Sex	25 YRS/M			Specimen Type	Tissue
Patient ID	012001300027			Collection Date	30-Jan-2020
Specimen ID	MOLQ/B-197-20			Report Date	17-Feb-2020

SURGICAL PATHOLOGY REPORT

Bartholins Cyst

DIAGNOSIS

BARTHOLINS CYST



SPECIMEN

Bartholins Cyst

GROSS

Received 2.6x1.1 cm long greyish white tissue piece. E/A

Microscopy

Section examined shows squamous lining epithelium with round to oval nucleus with cyst lined by cuboidal lining epithelium with fibrocollagenous tissue and large number of blood vessels. No granuloma seen. No malignant cells seen.

Note : All biopsy specimen will be stored for 15 (fifteen)days, block and slides for 5(five) years only from the time of receipt at the laboratory. No request ,for any of the above ,will be entertained after the due date.

Reference

- i) Rosai and Ackerman's Surgical Pathology.
- ii) Modern Surgical Pathology.

Gulshan Yadav, MD
Consultant Pathologist