

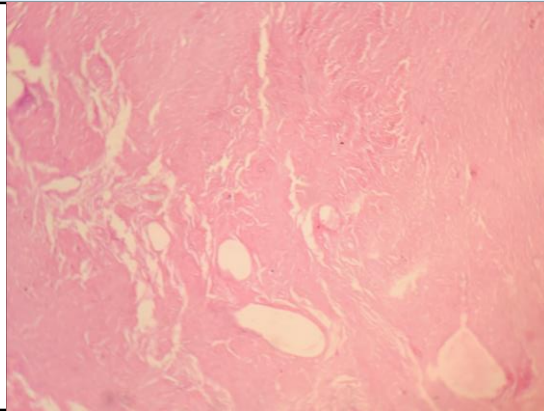
<b>Patient Name</b>	Mrs. SANGITA	<b>Client Name</b>	IRCC Hospital, Panchkula	<b>Specimen Received</b>	12-Feb-2020
<b>Age/Sex</b>	42 YRS/F			<b>Specimen Type</b>	Tissue
<b>Patient ID</b>	012002120003			<b>Collection Date</b>	12-Feb-2020
<b>Specimen ID</b>	MOLQ/B-288/2020			<b>Report Date</b>	15-Feb-2020

## SURGICAL PATHOLOGY REPORT

### Uterus with Cervix

#### DIAGNOSIS

#### LEIOMYOMA.



#### SPECIMEN

Uterus with Cervix

#### GROSS

Received 8x5.6 cm uterus with cervix with unilateral adnexa. Ovary size 5x3 cm. Cut section shows 2x2cm cyst with clear fluid. Already cut open 1x1cm, 0.5x1cm fibroid.

#### Microscopy

Section examined shows

- 1)Endometrium with proliferative phase
- 2)Myometrium with muscle bundles and Nabothian cyst
- 3)Cervix with mononuclear inflammatory cells
- 4)Ovary simple cyst and tube unremarkable
- 5)Fibroid with interlacing muscle bundle.

**Note :** All biopsy specimen will be stored for 15 (fifteen)days, block and slides for 5(five) years only from the time of receipt at the laboratory. No request ,for any of the above ,will be entertained after the due date.

#### Reference

- i) Rosai and Ackerman's Surgical Pathology.
- ii) Modern Surgical Pathology.

**Gulshan Yadav, MD**  
Consultant Pathologist