

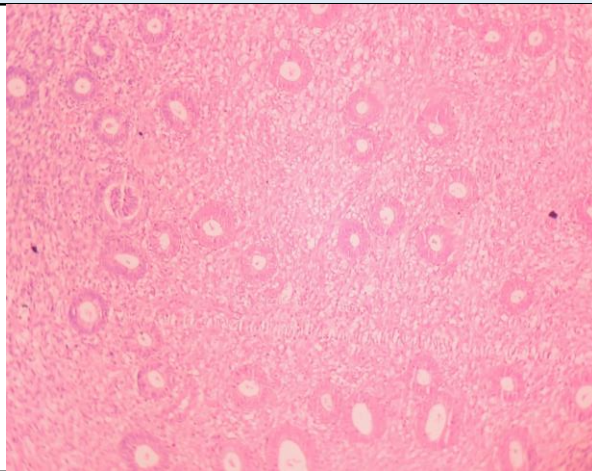
Patient Name	Mrs. KUSUM	Client Name	Lifeaid Wellness Centre	Specimen Received	11-Feb-2020
Age/Sex	35 YRS/F			Specimen Type	Tissue
Patient ID	012002110338			Collection Date	11-Feb-2020
Specimen ID	MOLQ/B-293/2020			Report Date	15-Feb-2020

SURGICAL PATHOLOGY REPORT

Endometrial polyp

DIAGNOSIS

ENDOMETRIAL POLYP.



SPECIMEN

Endometrial polyp

GROSS

Received multiple grayish white tissue piece.

Microscopy

Section examined shows small endometrial glands with cuboidal to columnar lining epithelium with round nucleus. Stroma shows mononuclear inflammatory cells. No granuloma seen. No malignant cells seen.

Note : All biopsy specimen will be stored for 15 (fifteen) days, block and slides for 5 (five) years only from the time of receipt at the laboratory. No request, for any of the above, will be entertained after the due date.

Reference

- i) Rosai and Ackerman's Surgical Pathology.
- ii) Modern Surgical Pathology.

A handwritten signature in black ink, appearing to read 'Gulshan', written over a light blue rectangular background.

Gulshan Yadav, MD
Consultant Pathologist