

Human Epidermal Growth Factor Receptor 2 Immunohistochemistry

Clinician

Clinician Name: Dr. Sandeep Batra
Medical Facility: Max Hospital
Pathologist: Not Provided

Test Description

Test is useful for determining overexpression of HER2 protein of gastric and esophageal adenocarcinoma in formalin-fixed, paraffin-embedded tissue sections (with reflex to FISH testing).

Clinical Information

Human epidermal growth factor receptor 2 (*HER2*), is a proto-oncogene located on chromosome 17q21 that encodes a transmembrane protein with tyrosine kinase activity, a member of the HER receptor family and is involved in signal transduction pathways, leading to cell growth and differentiation. Amplification and overexpression of the *HER2* gene have been associated with a shorter disease-free survival and shorter overall survival in gastric and gastroesophageal junction cancers, as well as breast, endometrial, and ovarian cancer.

Specimen

Sample Type: FFPE block SB-5852-19
Site: Recto-sigmoid Growth
Pathology ID: MOLQ/IHC-02022020
Disease: Colorectal Adenocarcinoma

Scoring

The scoring system is based on type and origin of tumor.

Score	Staining Pattern	Interpretation
0	No reactivity or membranous reactivity in <10% of cancer cells	Negative
1+	Faint or barely perceptible membranous reactivity in ≥10% if cancer cells; cells are reactive only in part of their membrane.	Negative
2+	Weak to moderate complete, basolateral or lateral membranous reactivity in ≥10% of tumor cells	Equivocal
3+	Strong complete, basolateral or lateral membranous reactivity in >10% of cancer cells.	Positive

Interpretation

Results are reported as positive (3+ HER2 protein expression), equivocal (2+), or negative (0 or 1+).

Equivocal (2+) cases will automatically reflex to FISH testing at an additional charge.

Methodology

Immunostaining for HER2 protein was done using PathnSitu Rabbit Anti-Human HER2 monoclonal (Clone EP3) antibody (#PR047)

References

1. Rosai and Ackerman's Surgical Pathology.
2. NCCN Guidelines Journal of the National Comprehensive Cancer Network 2006 4
3. Reporting Results of *HER2 (ERBB2)* Biomarker Testing of Specimens from Patients with Adenocarcinoma of the Stomach or Gastroesophageal Junction Angela N. Bartley Gastric HER2 Biomarkers (CAP)
4. Brandon S *et al.* HER2/neu Testing in Gastric Cancer by Immunohistochemistry. Arch Pathol Lab Med 2014 138
5. Ramin Azarhoosh *et al.* HER2/neu gene amplification in gastric adenocarcinoma and its relationship with clinical and pathological findings. J Gastrointest Oncol. 2017 8:6

Human Epidermal Growth Factor Receptor 2 (HER2/neu): (Score 2)

Microscopy Evaluation

HE Staining (Figure 1)

Tumor cells: 26%

Her2/neu by IHC: Score 2+

Percentage of cells with membrane staining: 25% (Weak immunostaining) (Figure 2)

HE Stained Section

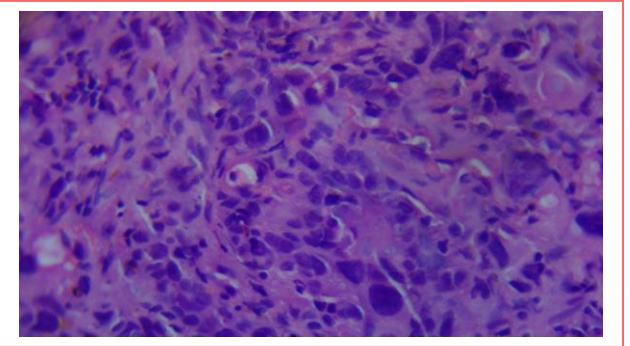


Figure 1

HER2/Neu IHC- Tumor

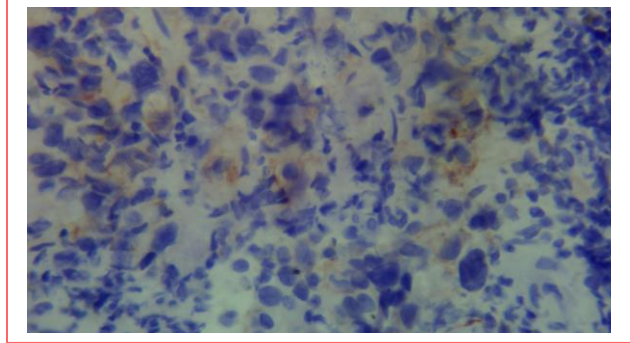


Figure 2

Reviewed By



Dr. Gulshan Yadav, MD
Head, Pathology