

Patient Name PARMINDER KATARIA
Age/Sex 47 YRS/M
Patient ID 012002090106
Specimen ID MOLQ/B-265-20

Client Name Shri Balaji Multispeciality
Hospital-Gurgaon

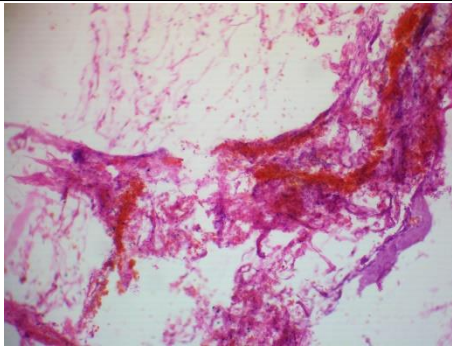
Specimen Received 09-Feb-2020
Specimen Type Tissue
Collection Date 09-Feb-2020
Report Date 14-Feb-2020

SURGICAL PATHOLOGY REPORT

Right Inguinal Hernia

DIAGNOSIS

HERNIAL SAC



SPECIMEN

Right Inguinal Hernia

GROSS

Received 9x6 cm grayish white cystic tissue piece.

Microscopy

Section examined shows fibrocollagenous tissue, mature adipose cells and blood vessels.

No granuloma seen. No malignant cells seen.

Note : All biopsy specimen will be stored for 15 (fifteen) days, block and slides for 5 (five) years only from the time of receipt at the laboratory. No request, for any of the above, will be entertained after the due date.

Reference

- i) Rosai and Ackerman's Surgical Pathology.
- ii) Modern Surgical Pathology.



Gulshan Yadav, MD
Consultant Pathologist