

Patient Name Ms. HAMIDI
Age/Sex 71 YRS/F
Patient ID 012002080220
Specimen ID MOLQ/B-268-20

Client Name Family Hospital and Surgical
Centre

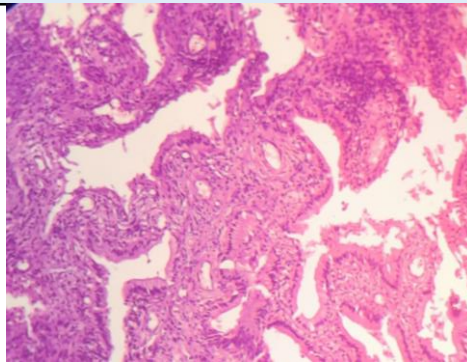
Specimen Received 07-Feb-2020
Specimen Type Tissue
Collection Date 07-Feb-2020
Report Date 13-Feb-2020

SURGICAL PATHOLOGY REPORT

Gall Bladder

DIAGNOSIS

CHOLECYSTITIS



SPECIMEN

Gall Bladder

GROSS

Received 4X2 cm long gall bladder already cut open without stones. Wall thickness 0.5 mm.

Microscopy

Section examined shows autolytic changes with ulcerative mucosa and Rokitansky-Aschoff sinus (irregularly shaped tubular structures lined by cuboidal lining epithelium with round to oval nucleus) with fibro collagenous tissue and inflammatory cells (lymphocytes).

Note : All biopsy specimen will be stored for 15 (fifteen) days, block and slides for 5 (five) years only from the time of receipt at the laboratory. No request, for any of the above, will be entertained after the due date.

Reference

- i) Rosai and Ackerman's Surgical Pathology.
- ii) Modern Surgical Pathology.

A handwritten signature in black ink, appearing to read 'Gulshan'.

Gulshan Yadav, MD
Consultant Pathologist