

Patient Name RANJU 47542
Age/Sex 29 YRS/F
Patient ID 012002070262
Specimen ID MOLQ/B-255-20

Client Name Pushpanjali Hospital (Rewari)
Specimen Received
Specimen Type
Collection Date
Report Date

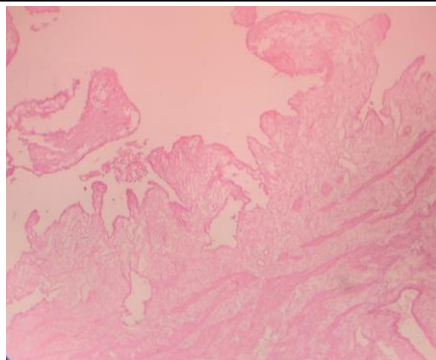
07-Feb-2020
Tissue
07-Feb-2020
13-Feb-2020

SURGICAL PATHOLOGY REPORT

Gall Bladder

DIAGNOSIS

CHOLECYSTITIS



SPECIMEN

Gall Bladder

GROSS

Received 6.2x3 cm long gall bladder without stones.

Microscopy

Section examined shows autolytic changes with ulcerative mucosa and Rokitansky-Aschoff sinuses (irregularly shaped tubular structures lined by cuboidal lining epithelium with round to oval nucleus) with fibro collagenous tissue and inflammatory cells (lymphocytes).

Note : All biopsy specimen will be stored for 15 (fifteen) days, block and slides for 5 (five) years only from the time of receipt at the laboratory. No request, for any of the above, will be entertained after the due date.

Reference

- i) Rosai and Ackerman's Surgical Pathology.
- ii) Modern Surgical Pathology.



Gulshan Yadav, MD
Consultant Pathologist